

AIRTTKC 2026  
ARTIFICIAL INTELLIGENCE AS A RESEARCH TOOL:  
TRANSFORMING  
KNOWLEDGE CREATION

**CHONDROFIBROMA - CASE REPORT OF 2 CASES**

**PRESENTED BY:-** Dr Vaibhav shah Faculty Sdc, Dr. Manjula M, Consultant Bangalore, Dr Krishna-Shama-Rao-MBBS,MDS-OMFS,FRCS(ED),FDSRC(ENG)GLENEAGLES HOSPITAL KARNATAKA

**INTRODUCTION;** Chondrofibromas are benign tumours of Mesenchymal tissue composed of hyaline cartilage. Chondrofibroma means presence of cartilaginous tissue in the fibroma. Chondrofibroma is an uncommon tumour in gnathic sites. They are thought to arise from vestigial cartilaginous rests. It can occur at any age (commonly between 3<sup>rd</sup> or 4<sup>th</sup> decades) of life. Chondrofibromas related to oral cavity have been reported to occur in extra osseous and intra osseous locations. Extra osseous lesions are found on the lateral tongue, in soft tissue of the cheek. They can be present by birth or even in 3<sup>rd</sup> or 4<sup>th</sup> decades of life as firm, painless, mucosa covered nodules. Chondrofibroma can become malignant, locally infiltrative and difficult to eradicate if left untreated. At times they may behave as low grade chondrosarcomas. The paper presents CASE REPORT OF 2 CASES of Chondro-fibroma treated

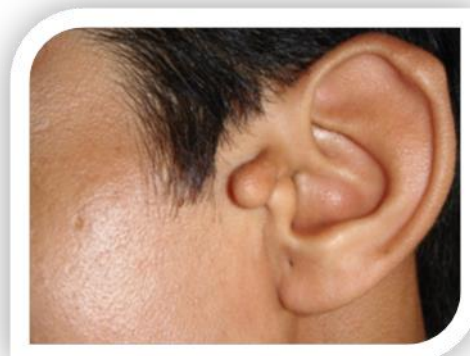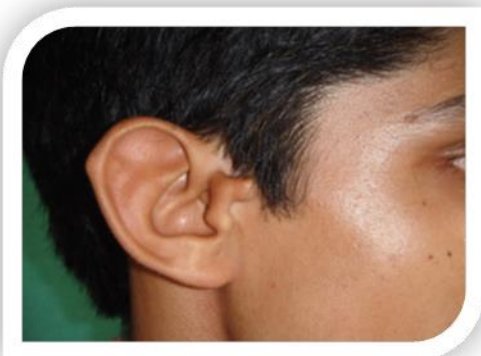**CASE REPORT**

A patient aged around 19 years reported with a chief complaint of skin growth in front of the both the ears since birth, Patient wanted to get them removed though growth of tissue didn't cause any functional discrepancies because it affected looks and patients were teased for appearance in the friend circle.

**FAMILY HISTORY:** one of patient cousin has a same type of growth in front of the ear and treated earlier.

**EXTRAORALLY: -** The submandibular, Preauricular and postauricular lymph nodes was non tender, not palpable. TMJ non tender, no deviation seen and no clicking sound heard.

**INTRAORALLY:-** patient has high narrow arched v shaped palate, two deciduous teeth retained, all third molars not erupted. No abnormalities detected in the soft tissues intra orally.



On examination: the skin growths were present one on each side on the tragus, measuring about

AIRTTKC 2026  
ARTIFICIAL INTELLIGENCE AS A RESEARCH TOOL:  
TRANSFORMING  
KNOWLEDGE CREATION

0.5 -1 cm in size, the skin on the growth appeared normal, no pulsations seen on the surface, there was no discharge from the growth.

**ON PALPATION:** There was no rise in temperature on the growth, the growth on the left side was soft in consistency whereas on the right side it was firm and cartilaginous extension from the tragus was felt. The growth was non tender and not compressible.

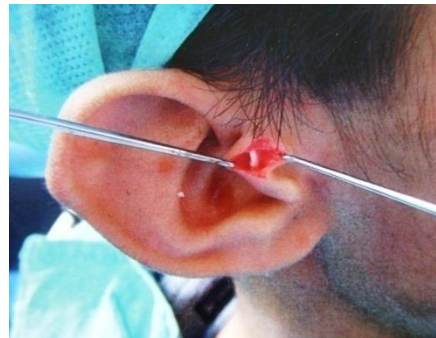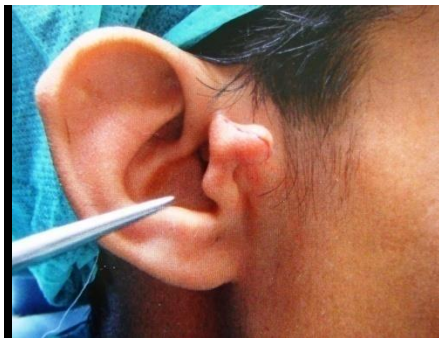
**PROVISIONAL DIAGNOSIS:** - made based on clinical examination & history as Lipoma/ fibroma/chondroma.

**TREATMENT PLAN:** - Surgical excision & sutures placed, specimen for histopathology for report, Patient to be recalled after one week for suture removal & follow up.

**INVESTIGATIONS:**-Basic investigations like Hb%, clotting time, bleeding time, RBS were done. The report revealed all readings were under normal limits.

**SURGICAL PROCEDURE:**- The surgical area was prepared by cutting the hair around the lesion, then scrubbing the area with povidone iodine. Left side; Local anaesthesia was obtained by infiltrating the 2% lignocaine with adrenaline around the growth. The growth was small and soft in consistency. The growth was held with Addison's tissue holding forceps and using a no.11 blade excision was done. Sutures were placed with 5-0 vicryl.

Right side;

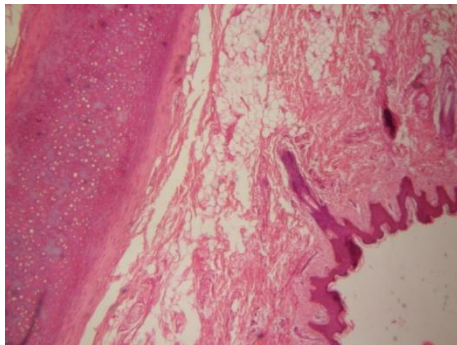


Local anaesthesia was obtained by blocking the preauricular nerve using 2% lignocaine with adrenaline. The growth on the right was little larger and there was cartilaginous extension. Therefore the incision was made on the crest of the growth to expose the cartilage, skin was undermined to reach the depth of extension. The growth was extended from tragus. The excess growth was trimmed and reshaped, excess skin was also trimmed. Then the sutures were placed using the 5-0 vicryl. Wokadine spray sprayed on the sutured area and patient was advised to take tab. Diclofenac and cap. Amoxicillin thrice daily for 5 days. Patient was recalled after one week for follow suture removal and follow up. Both specimen were collected in two different formaline bottles, labelled and sent to histopath for obtaining a final diagnosis.

**HISTOPATHOLOGY REPORT;**

The histopathological report revealed that lesion was diagnosed as Chondro-fibroma. The histological pictures were as follows.

AIRTTKC 2026  
ARTIFICIAL INTELLIGENCE AS A RESEARCH TOOL:  
TRANSFORMING  
KNOWLEDGE CREATION



The histological pictures show sub epithelial layer, connective layer, adipose tissue and the plenty of chondrocytes and fibrocytes in the connective tissue suggestive of cartilage. The H & E stains- showed the bundles of collagen fibres, fibrocytes and plenty of chondrocytes.

Chondrocyte are well encapsulated binucleated cells.

**DISCUSSION:-**Very few cases of chondrofibromas are reported in the literature.

56 PRIMARY HAND BONE TUMOURS  
EDINBURGH HAND CLINIC 1959-73 (*Jonathan & Lamb*)

Monostotic Enchondroma	35
Polyostotic Enchondroma	4
Ollier's Disease	1
Enchondroma	12
Osteoma	1
Osteoblastoma	1
<b>Chondrofibroma</b>	<b>1</b>
Chondrosarcoma	1
	56

*The Hand--Vol. 6 No. 3 1974 ; 275*

According to Jonathan & Lamb survey the incidence of chondrofibroma among the hand bone tumours was around 1.5%. Incidence of chondrofibroma in the head and neck region is even rarer. One case of chondrofibroma of the trachea was reported in the year 1936;

*Gatewood* in the year 1936, has reported a case of chondrofibroma of trachea., the patient had dyspnea , they treated with morphine & epinephrine were administered without relief.

Bronchoscopic examination showed an obstruction which had the appearance of normal mucous membrane. On x-ray a mass was found attached 1<sup>st</sup> & 2<sup>nd</sup> rings of trachea...

Lower tracheotomy was performed with relief of dyspnea. This mass was removed surgically.

*Chondrofibroma of the trachea. Report of a case.  
Gatewood, E. T: Arch. Otolaryng. 24: 92, 1936*

The etiology of chondrofibroma is thought to arise from the vestegeal remnants of the cartilagenous tissue.it can occur at any age,with no sex prediliction.chondrofibroma may have a tendency for transformation into chondromyxoid fibroma, which have a high tendency for malignant transformation as chondrosarcoma. Chondrofibromas can be treated surgically by excision or through intra dermal injections. In both cases we opted for surgical excision because lesion was small, accessibility was good and treatment would get over in one visit.

AIRTTKC 2026  
ARTIFICIAL INTELLIGENCE AS A RESEARCH TOOL:  
TRANSFORMING  
KNOWLEDGE CREATION

The intra lesion injections take long time for healing, requiring patient's frequent visits to hospital and patient will have to undergo pain of injection every time. Some patient may develop allergy for the solutions. Cryosurgery requires sophisticated equipments, costly and if slight negligence also causes the death of the neighbouring tissues.

**CONCLUSION;** Chondrofibroma can be left untreated, those causing pain by pressure on surrounding structures should be excised and curetted to remove the traces of tumor cells.

Some more studies have to be conducted and report of the all treated cases should be added to the literature for the benefit of the surgeons.

A simple skin growth in our case was diagnosed as chondrofibroma!

Therefore all Excisional biopsies should be sent for HP to make a final diagnosis and reporting should be done.

**REFERENCES;**

- 1) Enchondromata of bones of the hand. A review of 40 cases. (Jonathan & Lamb)The Hand -Vol6 No. 3; 275; 1974
- 2) Chondrofibroma of the trachea. Report of a case. (Gatewood E. T): Arch. Otolaryng. 24: 92, 1936
- 3) Chondromyxoid fibroma of the mandible diagnostic image cytometry findings and review of Literature. (Susan Muller, DMD, Ms, Bryan Whitaker, DDS)Oral Surg Oral-Med-Oral Pathol; 73; 465-8; 1992
- 4) Text Book of Oral Pathology by Nevil
- 5) Beily and Love's Text Book of Short Practise of Surgery
- 6) Shier's Text Book of Cysts and Tumours
- 7) Intra oral distraction for mandibular lengthening; technical innovation (P a Diner, E-M Kollar, journal of cranio-maxillofacial surgery; 24; 92- 95; 1996
- 8) Gherlinzoni FR, Rock M, Picci P. Chondromyxoid fibroma. The experience at the Istituto Ortopedico-Rizzoli. JBJS. 1983; 65(2):198-204.
- 9) Wu CT, Inwards CY, O'laughlin S, Rock MG, Beabout JW, Unni KK. Chondromyxoid fibroma of bone: a clinico pathologic review of 278 cases. Human-Pathol ;29(5):438-46.